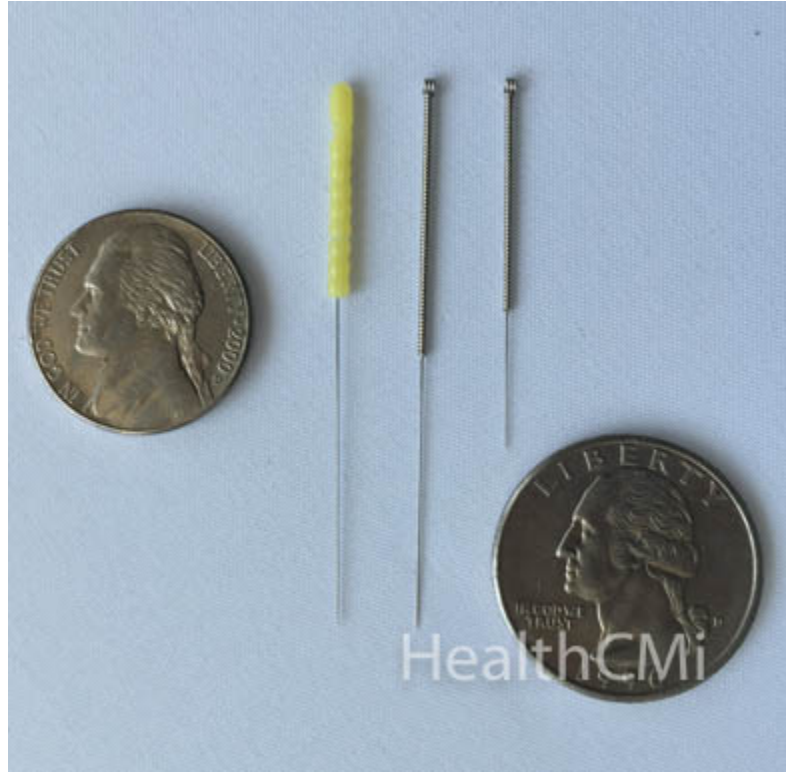


Acupuncture Inhibits Scar Formation

Published by [HealthCMi](#) on 27 July 2015.

Researchers discovered that a type of acupuncture, referred to as electroacupuncture, is effective for inhibiting hypertrophic scar formation. Electroacupuncture is a form of acupuncture wherein an electric current is run between the needles. A hypertrophic scar is a cutaneous condition involving excessive collagen deposits during wound healing. This affects aesthetic appearances and may result in various forms of psychological dysfunction in serious cases. Although different treatment strategies targeted at hypertrophic scars are practiced, there is yet to be a definitive treatment protocol for this condition. The results demonstrate that electroacupuncture regulates and impedes regeneration of fibrous tissues, prevents adhesions during recuperation, and improves blood circulation at scar areas. Also, electroacupuncture is effective in softening and lightening scars, decreases the size of scars, and reduces scar thickness.



A recent experiment was conducted by researchers at Yantai Binzhou Medical University to investigate acupuncture's ability to prevent scar formation. A total of 18 New Zealand rabbits were randomly distributed into 3 groups. The control group received manual acupuncture. Group A received electroacupuncture using continuous frequency current. Group B received electroacupuncture using electrical current with alternating frequencies.

Methodologies

The researchers used a Huatuo brand electroacupuncture machine and sterile, single-use acupuncture needles of size 0.25 mm X 0.25 mm. All rabbits were anesthetized and had their ears marked with four 1.5 cm X 1.5 cm squarish surgical wounds, each distanced at least 1 cm from another. After sterilization, researchers cut the skin to create wounds. After 20 days, they repeated the process above by cutting open the original wound and removing new tissues and created new wounds the size of 1.5 cm x 1.5 cm. At this point, the wounds were allowed to heal naturally.

Intervention

When all models were ready, researches practiced the following steps daily for 30 days.

- Control group: Insertion of acupuncture needles was diagonal, 0.5 cm from the hypertrophic wounds using 4 needles. The needles were inserted to a depth of 0.5 cm and were retained for 15 minutes.
- Group A: Researchers connected the top of the needles to the electroacupuncture machine and applied 2 mA continuous current for 15 minutes at wound areas.
- Group B: Alternating 2 and 100 Hz current of 2 mA was applied. Needle retention time was 15 minutes.

Researchers collected hypertrophic scar samples from 2 randomly selected rabbits in every group at the 10th, 20th, and 30th day. All rabbits which had their samples taken once and were not reused. Based on the samples collected at the 10th, 20th, and 30th day, researchers analyzed and recorded the areas, thickness, color, blood vessel distribution, and softness of all hypertrophic scars. Samples were monitored with an optical microscope with staining to tabulate scar proliferation indexes. All groups showed progress in the scoring of hypertrophic scars, however, the scar proliferation indexes from group A and B were vastly different from that of the control group. Electroacupuncture significantly inhibited scar formation. This includes an overall smaller size, less thickness, less discoloration, better uniformity of tissue, and less deformities. Overall, electroacupuncture produced significantly superior patient outcomes over the control group. Group B, using alternating frequency electroacupuncture, had the best scores.



Example of an Electroacupuncture Device

The researchers found electroacupuncture helpful in softening and lightening scars. Electroacupuncture also decreased the size of scar areas and thickness. Continuous frequency electroacupuncture produced less treatment results than alternating frequencies. The theoretical basis for these differences has yet to be fully elucidated. Based on the data, the researchers

concluded that electroacupuncture is useful in inhibiting hypertrophic scar formation. Alternating frequencies produce better clinical results than continuous frequency current. Overall, electroacupuncture continues to gain greater recognition for the treatment of hypertrophic scar prevention and reduction. This laboratory experiment confirms efficacy.

Reference:

Shi Hui, Yin Rongchao, Dong Ying. The effect of different waveform electric acupuncture on inhibiting hyperplastic scar on the the rabbit ear, Journal of Binzhou Medical University, 2015 (3).